

INTERNSHIP

F U K U O K A

Kyushu University Hospital

By Panda Chayanit Sirinanthasakul





Internship

26 Feb - 29 Mar

working with

Surgery 1

Surgery 2

Oral and Maxillofacial surgery

6 works

3 welcome party

21 cases observe

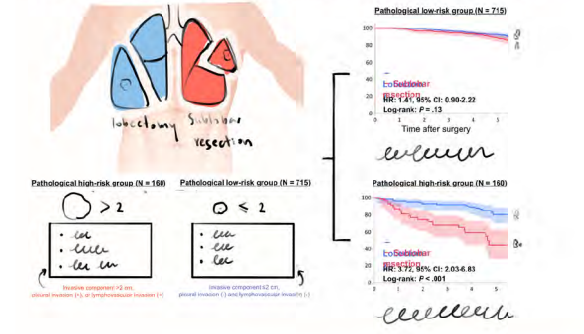
15 places sight seeing

Works

01 Visual Abstract

Is sublobar resection feasible for pathological high-risk NSCLC clinically staged I ≤2 cm?

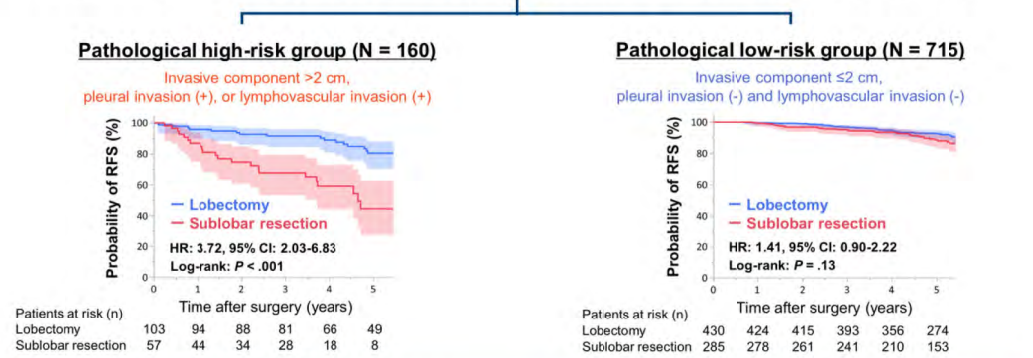
Multicenter retrospective analysis from 5 institutions (January 2012- December 2018)
 Patients with pathological stage I NSCLC clinically diagnosed cT1N0 with total tumor size ≤2 cm (N = 875)



Draft

Is sublobar resection feasible for pathological high-risk NSCLC clinically staged I ≤2 cm?


- Multicenter retrospective analysis from 5 institutions (January 2012- December 2018)
- Patients with pathological stage I NSCLC clinically diagnosed cT1N0 with total tumor size ≤2 cm (N = 875)



Sublobar resection is feasible for low-risk pathologic stage I NSCLC cases; high-risk cases benefit more from lobectomy. Enhanced preoperative assessments are necessary to accurately predict high-risk pathological factors.

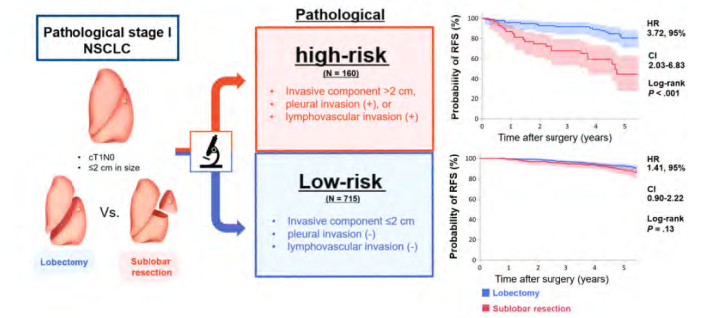
NSCLC, non-small cell lung cancer; RFS, recurrence-free survival; HR, hazard ratio; CI confidence interval

Contact with dr.Takaki via email



Is sublobar resection feasible for pathological high-risk NSCLC clinically staged I ≤2 cm?

- Multicenter retrospective analysis from 5 institutions (January 2012- December 2018)

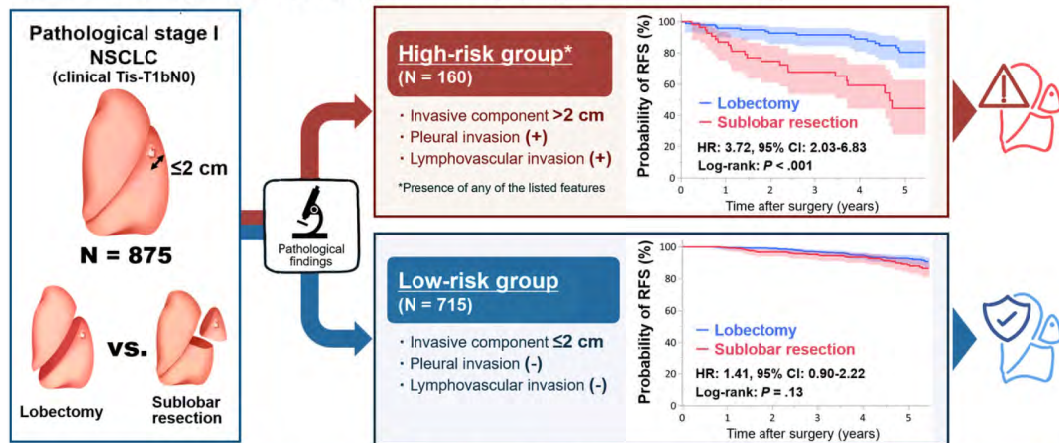


01 Visual Abstract

Final

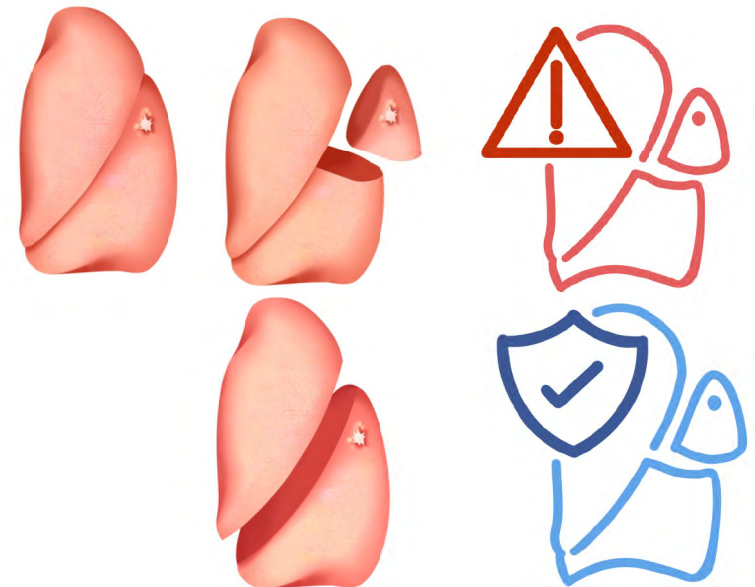
Is sublobar resection feasible for pathological high-risk NSCLC clinically staged I ≤ 2 cm?

• Multicenter retrospective analysis from 5 institutions (January 2012- December 2018)



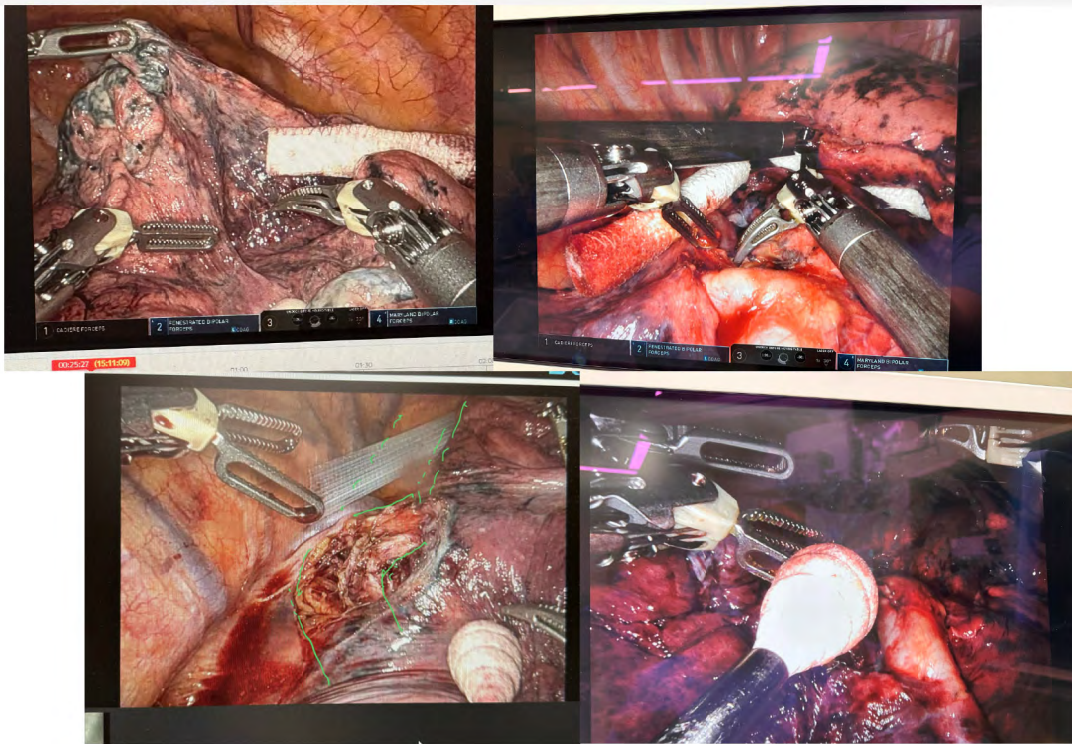
Sublobar resection is feasible for low-risk pathologic stage I NSCLC cases; high-risk cases benefit more from lobectomy. Enhanced preoperative assessments are necessary to accurately predict high-risk pathological factors.

NSCLC, non-small cell lung cancer; RFS, recurrence-free survival; HR, hazard ratio; CI confidence interval



0 2 L U N G S U R G E R Y

With Da Vinci hand



Left hand 1



Left hand 2

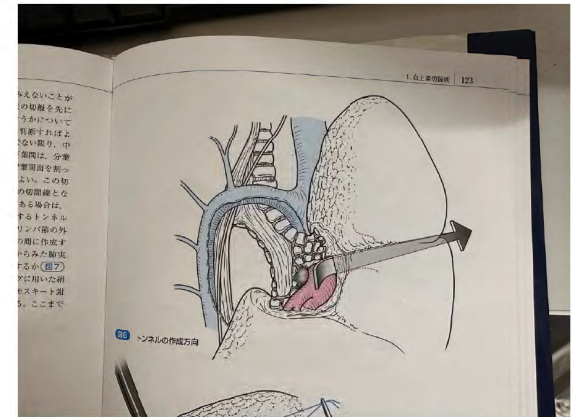
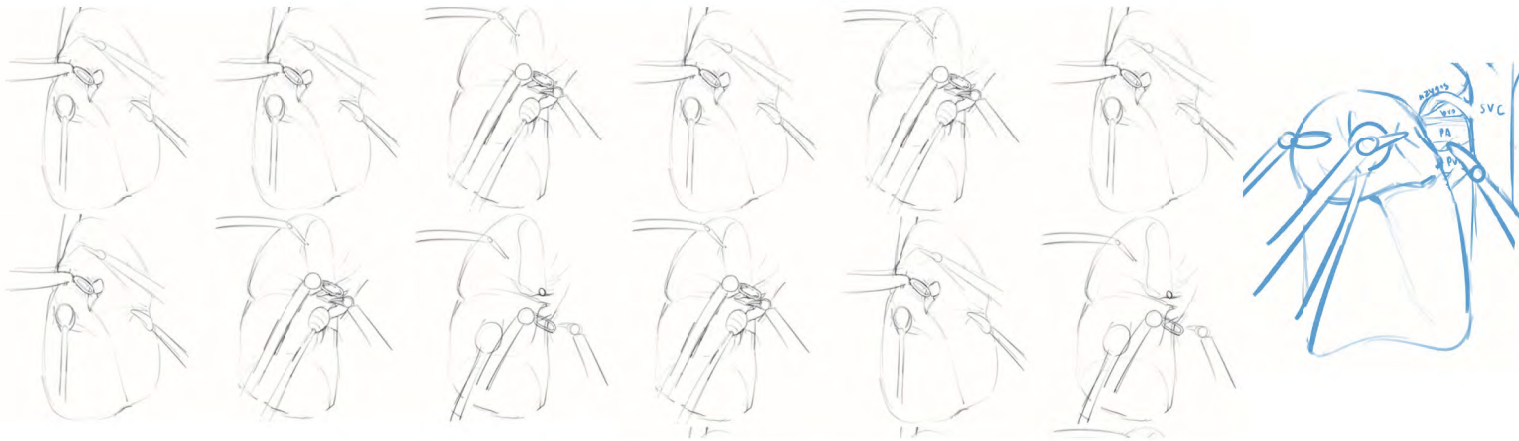


Right hand



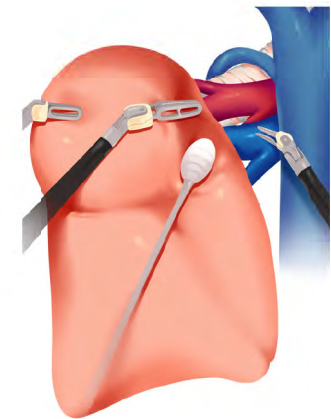
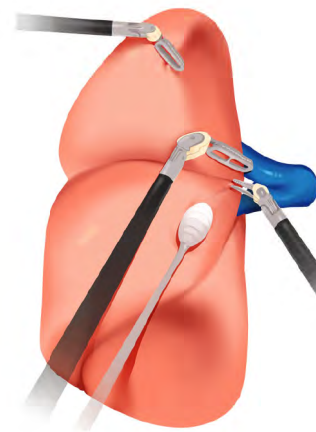
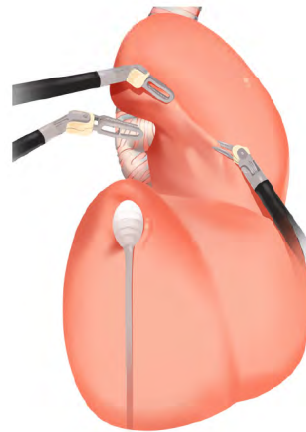
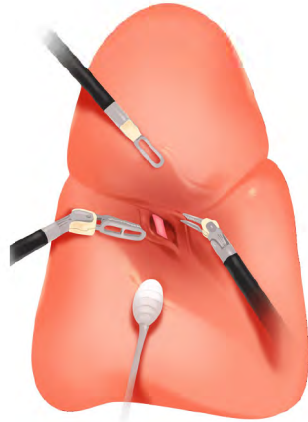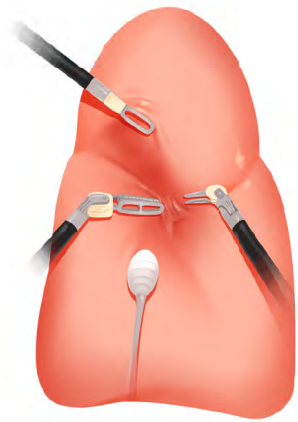0 2 L U N G S U R G E R Y

With Da Vinci hand



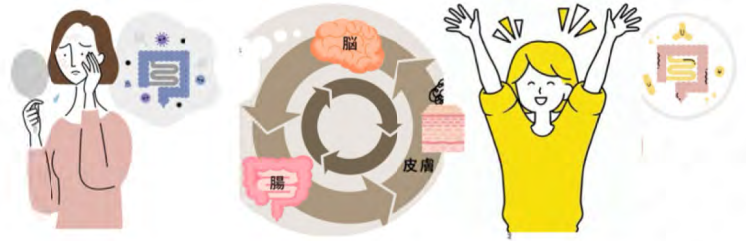
0 2 L U N G S U G E R Y

With Da Vinci hand

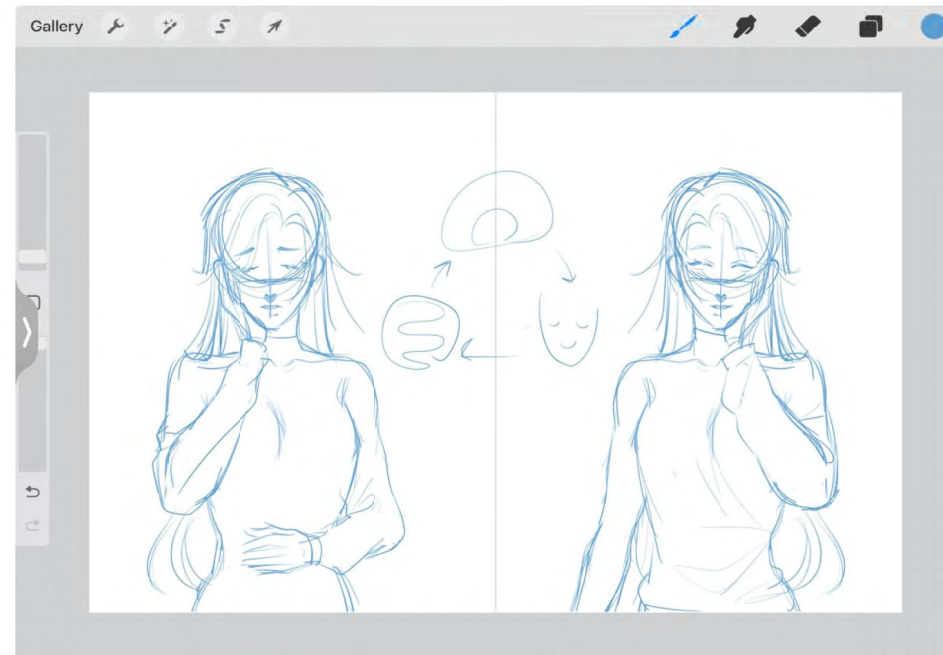
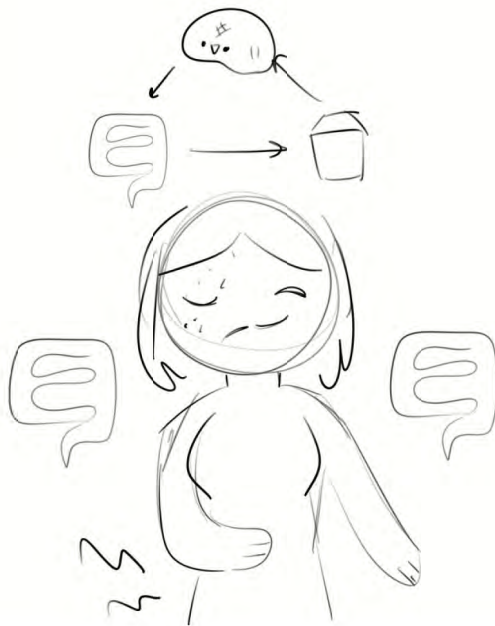

03 Brain gut skin interaction

for Kinuko san clinic



Brief

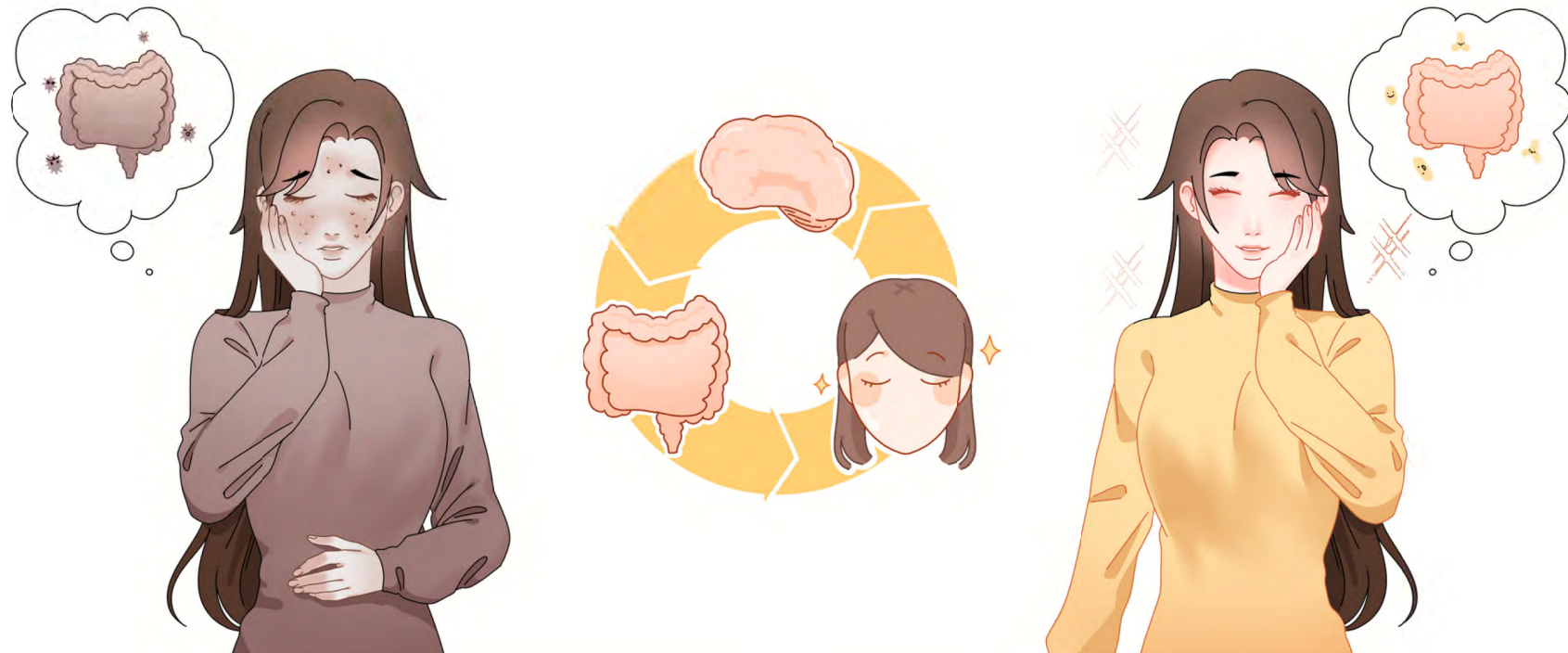



Draft

— 2024

03 Brain gut skin interaction

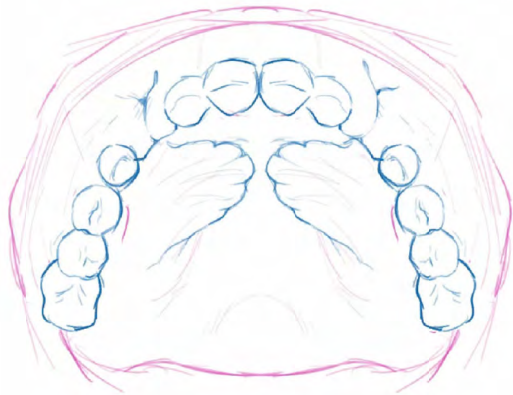for Kinuko san clinic



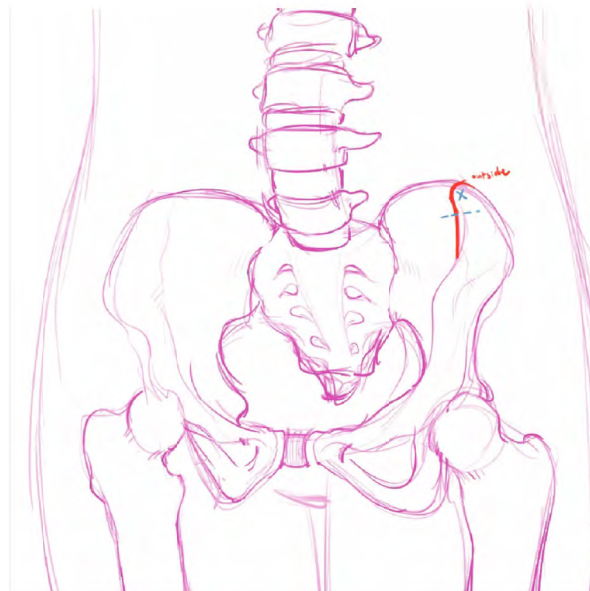
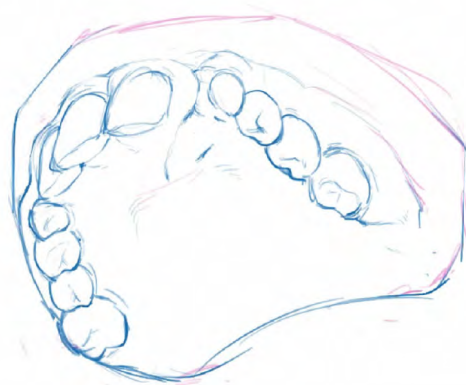

04 Cleft palate

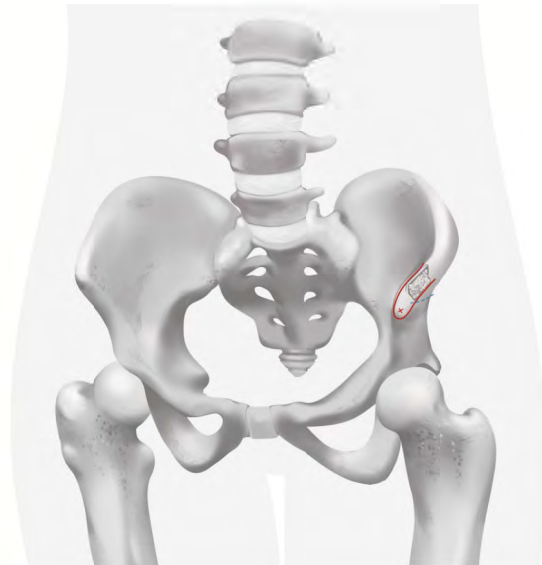
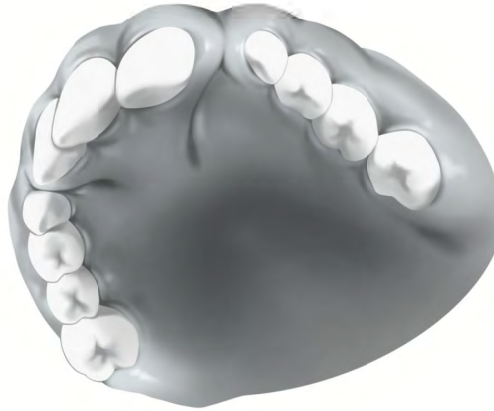
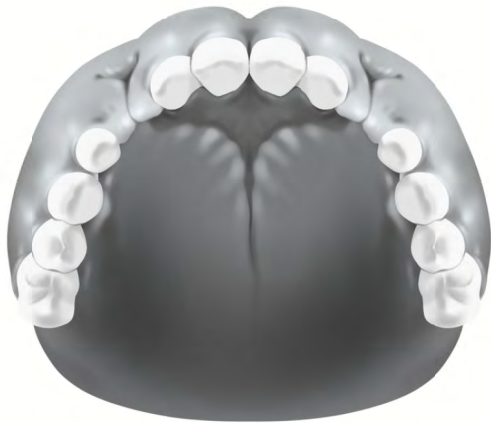6EDC 21/12 CDE 6



6EDC 21/1 CDE 6

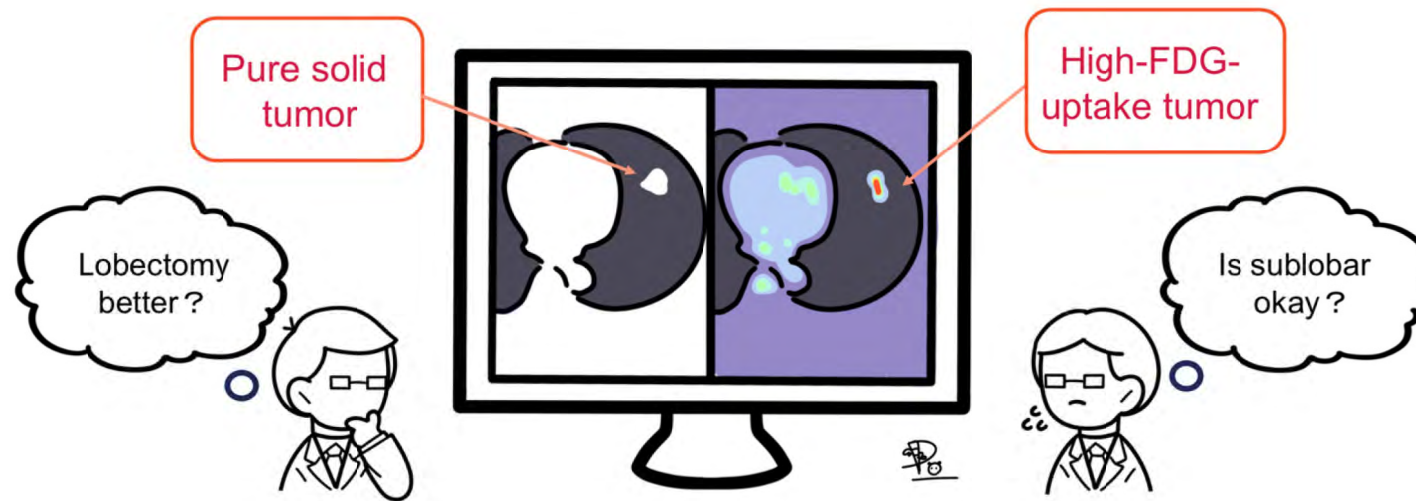


04 Cleft palate

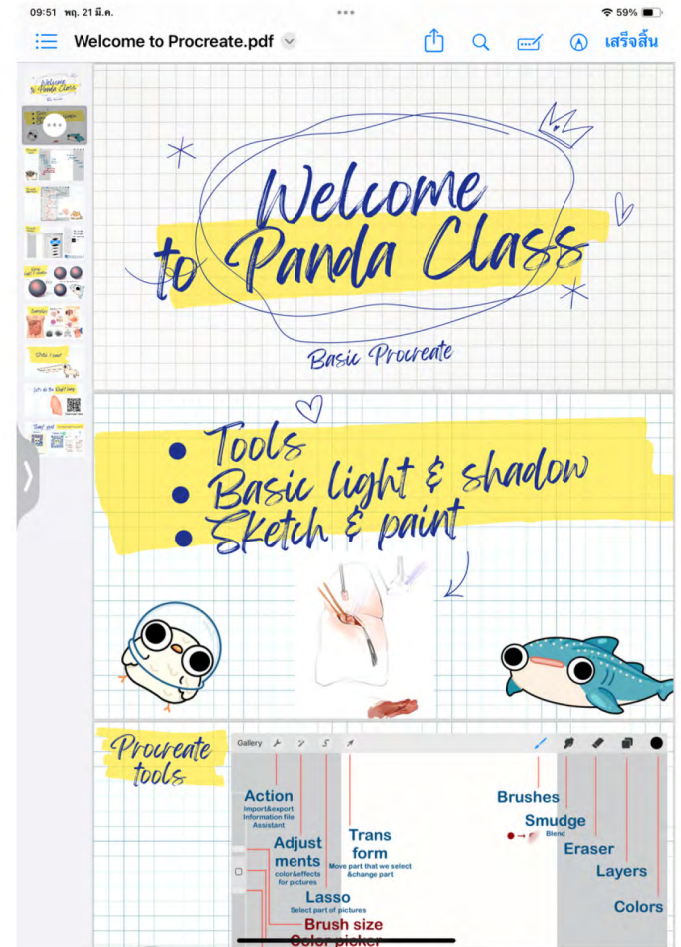
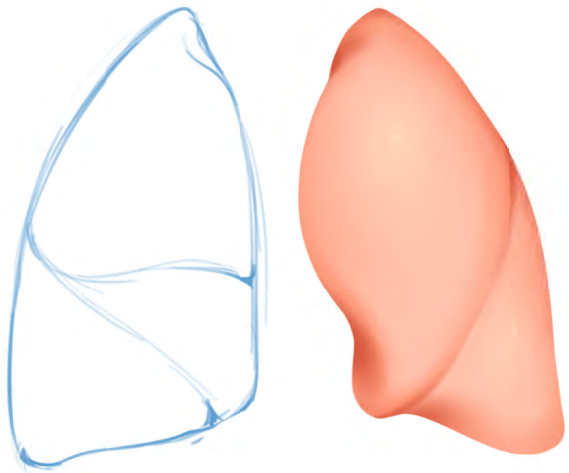


05 icon for presentation

Concern about surgical procedure in clinical practice



06 Procreate class



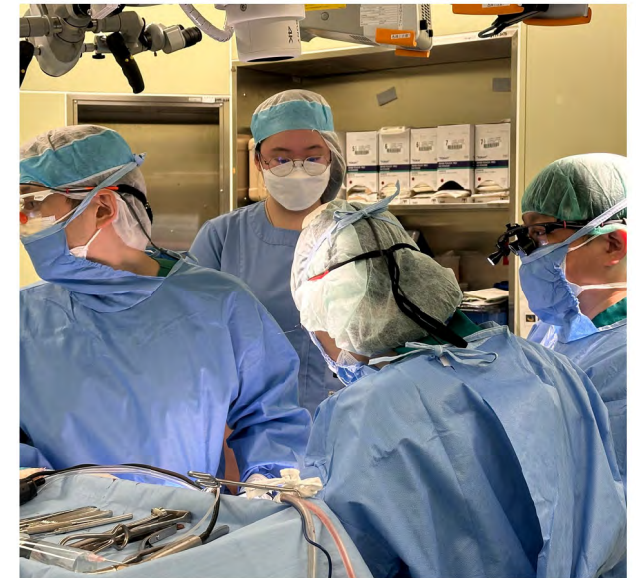06 Procreate class

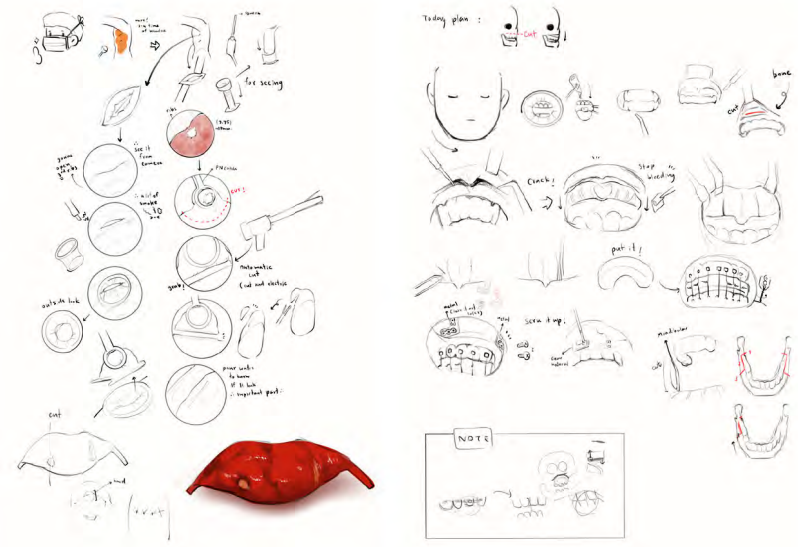
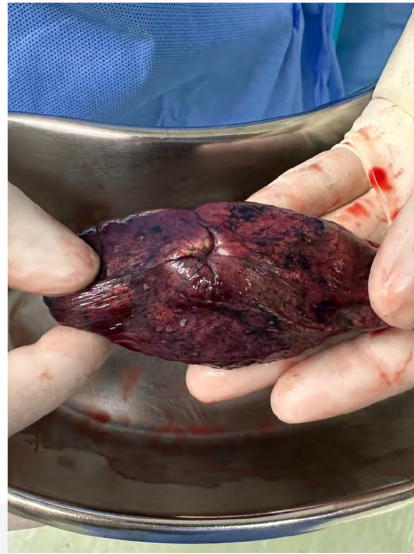
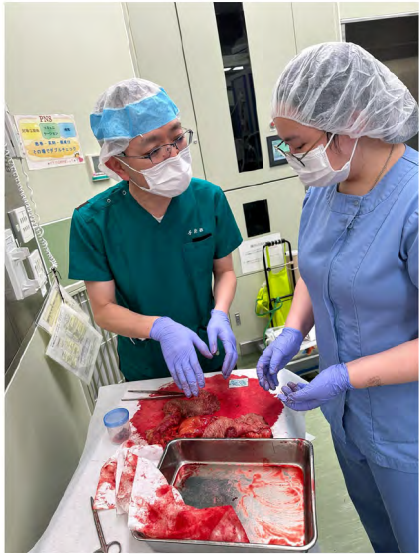
Observation in operation room

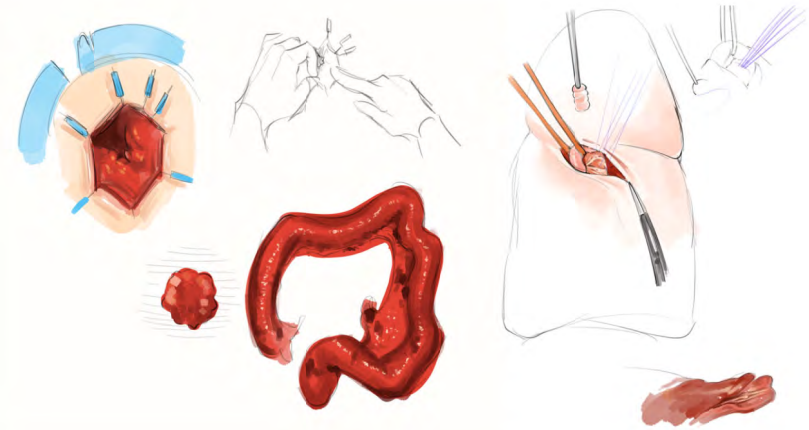
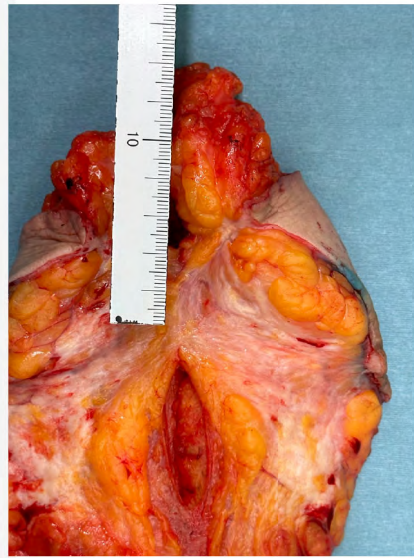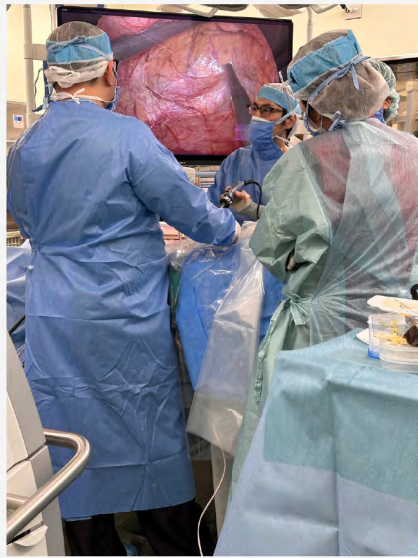Observe

- **get rid off salivary stone**
- **tumor**
 - lung
 - mandibular
 - breast
 - spine
 - stomach
 - tongue
 - buccal
 - colon
- **transpant**
 - liver
 - kidney
- **correct the chin position**
- **palatal torus**
- **robot surgery**





Observe



Party & Sightseeing

welcome party




with TEMDEC staff

**with Oral surgery
Shiho san and staff**



**with Surgery 1
Tomoyoshi san and
Takaki san
(I forgot to take a picture)**



2024


Sightseeing



Kushida Shrine



Miyajidake-jinja Shrine





Dazaifu Shrine

Sightseeing



Umi no nakamichi



interactive digital art by team lab

Sightseeing



Beseball game with Shiho san and Dr.tip





THANK YOU

SPACIAL THANK

TAKAKI SAN, TOMOYO SAN, SHIHO SAN, KINUKO SAN,
TEMDEC STAFF, OVEX STAFF, SURGERY 1, SURGERY 2,
ORAL AND MAXILOFACIAL SURGERY