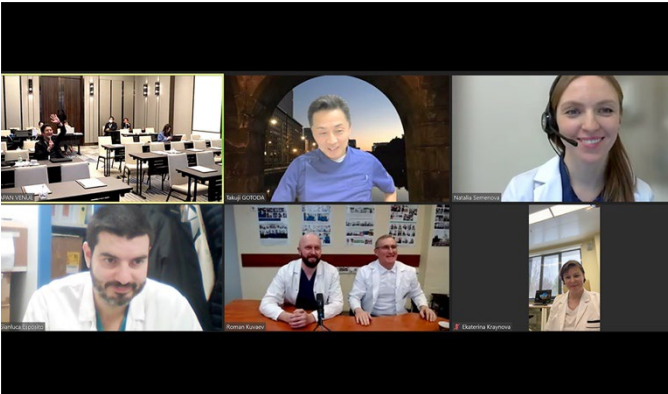

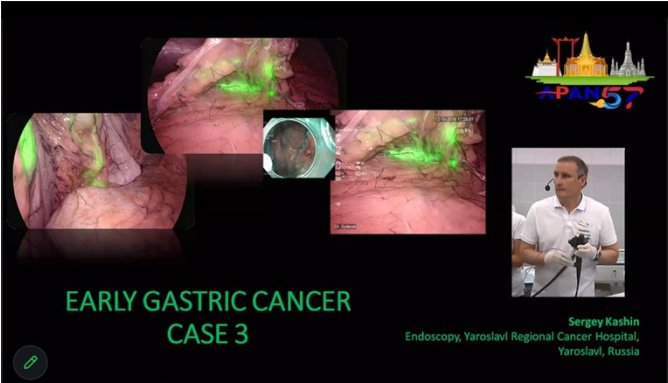
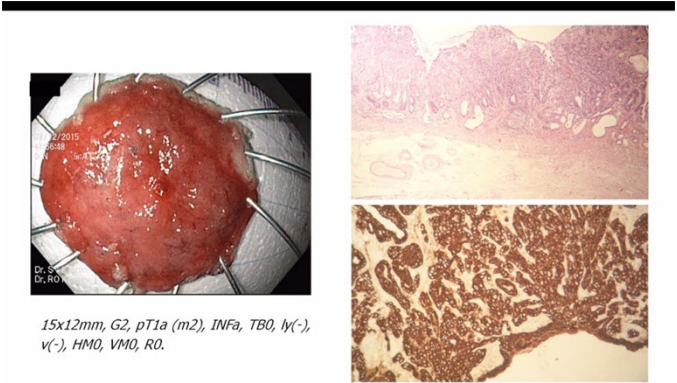
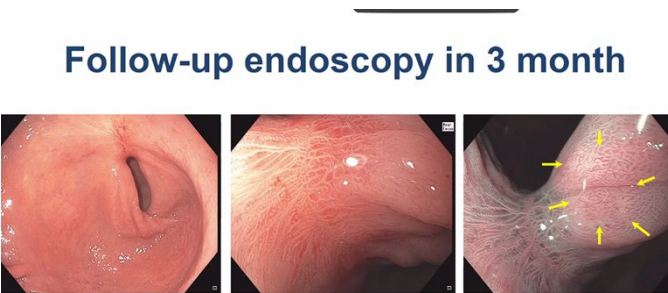



| 【 Connecting institutions 】  | 【 Comments 】  |
|--|---|
| <p>Eastin Grand Hotel Phayathai (Thailand), Yaroslavl Regional Cancer Hospital (Russian Federation), Kyushu University Hospital (Japan), Cancer Institute Hospital of JFCR (Japan), Loginov Moscow Clinical Scientific Center (Russian Federation), Institute of Plastic Surgery and Cosmetology, Moscow (Russian Federation), Tomsk Regional Oncology Center (Russian Federation), Moscow City Oncology Hospital No. 62 (Russian Federation), Kindai University (Japan), Sapienza University of Rome (Italy), Chulalongkorn University (Thailand)</p> | <p>Endoscopic Network Expert Team (Endo-NET) Workshop was conducted within the framework of 57th APAN with the topic “What to do after gastric ESD. Challenging cases”. Current evidence data and practical issues of different patient management after endoscopic submucosal dissection for early gastric cancer were discussed with the panel of faculty experts from Japan, Russia and Italy.</p> |
|    |  <p>Roman Kuvaeв</p>   |
| <p>Monitor shows connected sites</p>   | <p>Teleconference view at Yaroslavl Regional Cancer Hospital</p>  |
| <p>Picture taken at : Kyushu University Hospital</p>   | <p>Picture taken at : Kyushu University Hospital</p>  |
|  <p>EARLY GASTRIC CANCER CASE 3</p> <p>Sergey Kashin<br/>Endoscopy, Yaroslavl Regional Cancer Hospital,<br/>Yaroslavl, Russia</p>   |  <p>15x12mm, G2, pT1a (m2), INFa, TBO, ly(-), v(-), HMO, VMO, RO.</p>   |
| <p>A presented slide</p>   | <p>A presented slide</p>  |
| <p>Picture taken at : Kyushu University Hospital</p>   | <p>Picture taken at : Kyushu University Hospital</p>  |
| <p><b>Follow-up endoscopy in 3 month</b></p>  <p>Local recurrence in the area of the postoperative scar (biopsy – G1 adenocarcinoma)</p> <p>Abdominal ultrasonography, computed tomography: no signs of recurrence or lymph node metastasis</p>   |  <p>Natalia Semenova</p>  |
| <p>A presented slide</p>   | <p>Dr. Semenova makes a comment</p>   |
| <p>Picture taken at : Kyushu University Hospital</p>   | <p>Picture taken at : Kyushu University Hospital</p>  |