

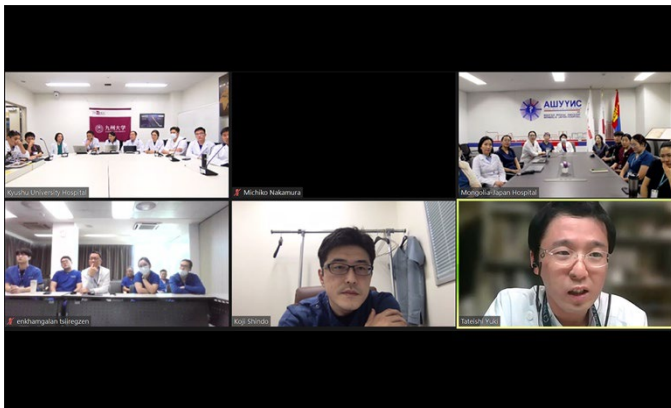2023.12.20

【 Connecting institutions 】

Kyushu University Hospital (Japan),  
Mongolian National University of Medical Sciences (Mongolia),  
Mongolia-Japan Hospital (Mongolia),  
Second State Central Hospital Mongolia (Mongolia),  
UB Songdo Hospital (Mongolia),  
First Central Hospital of Mongolia (Mongolia)

【 Comments 】

A case discussion was held between Mongolia and KUH. A gastric SMT case was presented from MJH, and the indication for LECS was discussed among surgeons, endoscopists, and pathologists. In the latter half of the meeting, a Mongolian doctor who had trained at KUH presented her experiences at KUH. It was an excellent meeting where the presence of KUH was demonstrated.



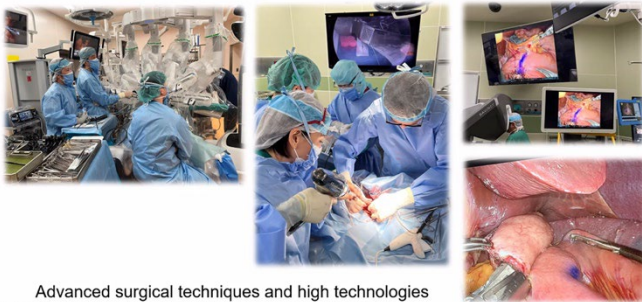Monitor shows connected sites

Picture taken at : Kyushu University Hospital

Dr. Baatarsuren (ctr. ) makes a comment

Picture taken at : Kyushu University Hospital

Observed surgeries at the Kyushu University hospital



Advanced surgical techniques and high technologies

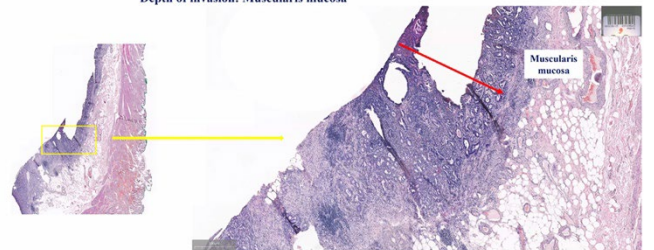
A presented slide

Picture taken at : Kyushu University Hospital




Microscopic (histology) description

Depth of invasion: Muscularis mucosa



A presented slide

Picture taken at : Kyushu University Hospital



Teleconference view at Kyushu University Hospital

Picture taken at : Kyushu University Hospital



Teleconference view at Kyushu University Hospital

Picture taken at : Kyushu University Hospital