

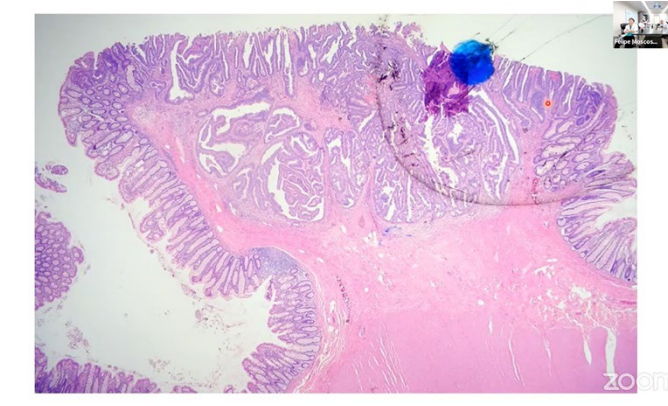





【 Connecting institutions 】	【 Comments 】
<p>KKyushu U H (Japan), Clinica Alemana (Chile), National Cancer Institute of Chile (Chile), San Juan de Dios H (Chile), The National Institute of Medical Sciences and Nutrition (Mexico), Universidad Nacional Autonoma de Mexico (Mexico), Centro Mexicano de Enfermedades Digestivas, Garcia Gineres office (Mexico), H Vita Batel (Brazil), H Nossa Senhora das Gracias (Brazil), H de Amor de Barretos (Brazil), Mackenzie Evangelical U H (Brazil) and 13 of others</p>	<p>In the last meeting, we presented two interesting cases. First, a small colonic lesion with endoscopic features of advanced cancer, finally solved by surgery, with interesting pathological images. And a clinical case of a patient with strong history of family cancer and carrier of CDH1 mutation, with a very fruitful discussion about offering the patient endoscopic surveillance follow-up versus surgery.</p>
	
<p>Monitor shows connected site Picture taken at : Kyushu University Hospital</p>	<p>Dr. Kashida makes a presentation Picture taken at : Kyushu University Hospital</p>
	
<p>A presentation slide Picture taken at : Kyushu University Hospital</p>	<p>A presentation slide Picture taken at : Kyushu University Hospital</p>
	
<p>Teleconference view at Clinica Alemana Picture taken at : Kyushu University Hospital</p>	<p>Dr. Uedo makes a comment Picture taken at : Kyushu University Hospital</p>