

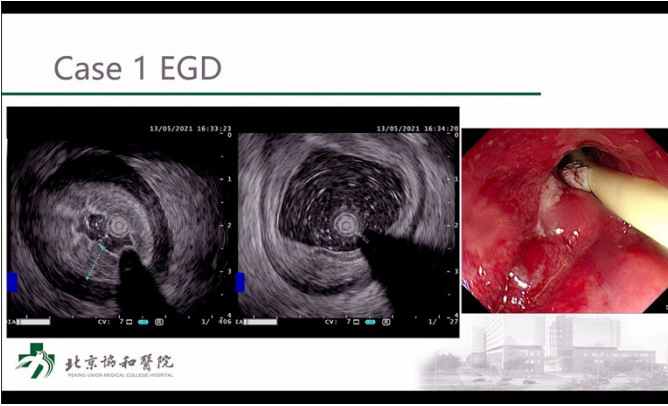
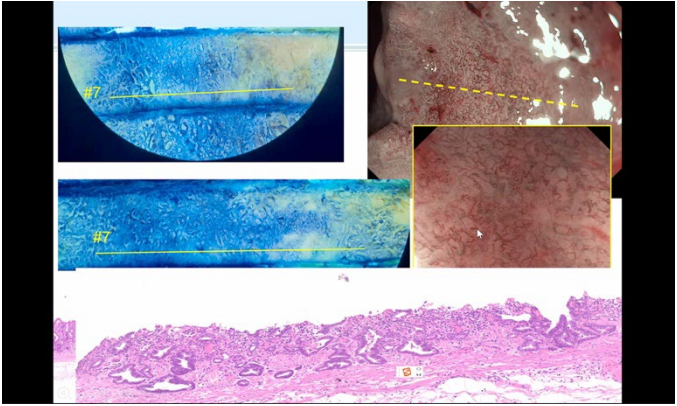
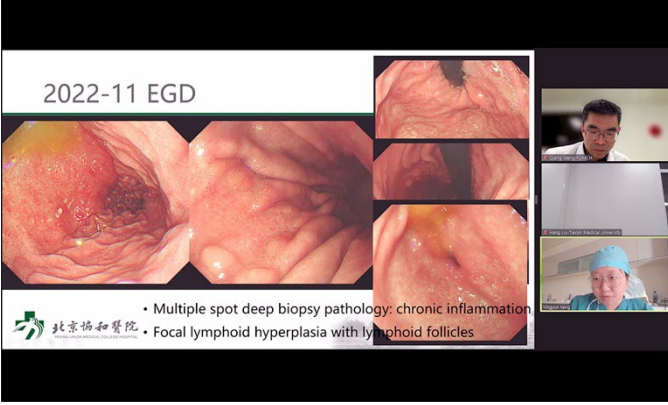



【 Connecting institutions 】	【 Comments 】
<p>Peking Union Medical College H (China), Fudan U Zhongshan H (China), Tianjin Medical U (China), Nanfang H, Southern Medical U (China), Fukuoka U Chikushi H (Japan), Kyushu U H (Japan), Shandong Province H (China), Chinese Center For Disease Control And Prevention (China), Juntendo U (Japan), Novosibirsk State Medical U Novosibirsk State Regional Clinical H (Russian Federation), Beijing H (China), Cancer H, Chinese Academy of Medical Sciences (China), Nanjing Drum Tower H (China), Beijing Friendship H, Capital Medical U (China), Fujian Provincial H (China), Viet Duc H (Vietnam), Kathmandu Marriott Hotel (Nepal)</p>	<p>We have an in-depth and thorough discussion for four cases in this Teleconference. For diffuse gastric lesions, the compliance and stiffness of the gastric wall are important to determine whether they are benign or malignant. Sometimes, a repeated multipoint deep biopsy is necessary for a definite diagnosis. We also discussed how to diagnose mixed-type EGC through endoscopic manifestations and how to classify and determine the degree of curative resection in pathology.</p>
	
<p>Monitor shows connected sites Picture taken at : Kyushu University Hospital</p>	<p>Dr. Liu makes a presentation Picture taken at : Kyushu University Hospital</p>
	
<p>A presentation slide Picture taken at : Kyushu University Hospital</p>	<p>A presentation slide Picture taken at : Kyushu University Hospital</p>
	
<p>A presentation slide and connected sites Picture taken at : Kyushu University Hospital</p>	<p>Dr. Yao makes a comment Picture taken at : Kyushu University Hospital</p>