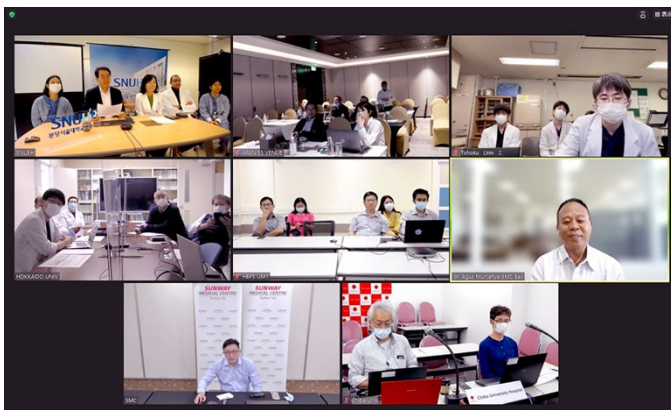


【 Connecting institutions 】

Kathmandu Marriott Hotel (Nepal), Seoul National University Bundang Hospital (Korea, Republic of), Chiba University (Japan), Hokkaido University (Japan), Tohoku University (Japan), University of Malaya (Malaysia), Sunway Medical Centre (Malaysia), Yangon Specialty Hospital (Myanmar), Kyushu University Hospital (Japan), BIMC Hospital Nusa Dua (Indonesia)

【 Comments 】

The 55th APAN Meeting -HPB session was connected with each participating organization using a video conference system. Doctors from each institution listened to the presentation of the presenter's surgical experience and knowledge and had time to answer questions. The lecture plays a video clip about HPB surgery. The event ended successfully, and it was a meaningful time to share knowledge.



Monitor shows connected site

Picture taken at : Kyushu University Hospital




Dr. Bong makes a presentation

Picture taken at : Kyushu University Hospital

**Histology report**

- Multinodular lesion with hemorrhagic areas (max diameter 8cm)
- Diagnosis = Undifferentiated Primary liver sarcoma
- Mitoses > 20/HPF
- Tumour necrosis <50%
- R<sub>0</sub> resection – nearest parenchymal margins 3mm




A presentation slide

Picture taken at : Kyushu University Hospital

**Background**

• **Optimal extent of resection for Hepatocellular carcinoma**

Anatomical resection	Non-anatomical resection
<ul style="list-style-type: none"><li>• Better Overall survival</li><li>• Better disease free survival</li></ul>	<ul style="list-style-type: none"><li>• Lower incidence of an inadequate future liver remnant</li></ul>
<ul style="list-style-type: none"><li>• High risk of postoperative liver dysfunction</li></ul>	<ul style="list-style-type: none"><li>• High risk of local recurrence</li></ul>



Liu H et al. World J Gastrointest Oncol. 2021  
Tomalia S et al. J Am Coll Surg. 2009  
Cucchetti A et al. Ann Surg Oncol. 2012


A presentation slide

Picture taken at : Kyushu University Hospital



Teleconference view at Seoul National U Bundang H

Picture taken at : Seoul National University Bundang Hospital



Teleconference view at Chiba University

Picture taken at : Chiba University