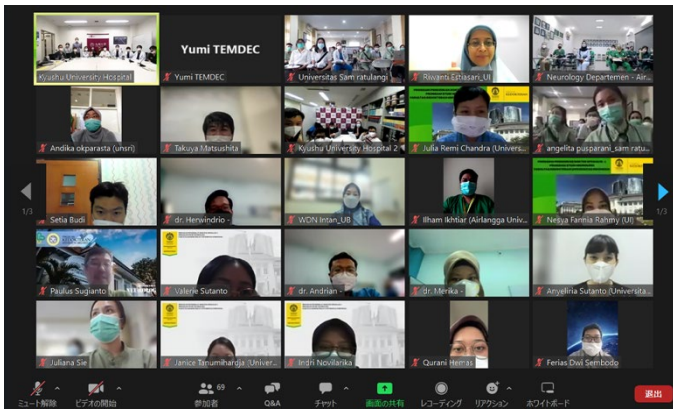


【 Connecting institutions 】

University of Indonesia (Indonesia), Sam Ratulangi University (Indonesia), Gadjah Mada University (Indonesia), Brawijaya University (Indonesia), Sriwijaya University (Indonesia), Sebelas Maret University Dr. Moewardi Hospital (Indonesia), Airlangga University (Indonesia), Kyushu University Hospital (Japan), Kochi University (Japan)

【 Comments 】

Japanese neurologists from Kyushu university hospital and Kochi university hospital, and Indonesian neurologists participated in the 33rd Indonesian neuroimmunology case teleconference. We discussed the diagnosis and management of a patient presenting headache, gradual visual loss, and spinal cord lesions. We have taken a big step toward the solution to the problem.



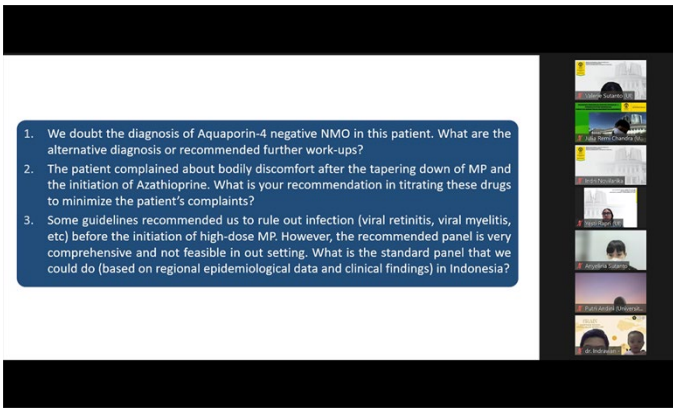
Monitor shows connected sites

Picture taken at: Kyushu University Hospital



An engineer from Indonesia(It.) establishes a connection

Picture taken at: Kyushu University Hospital



A presentation slide

Picture taken at: Kyushu University Hospital



Dr. Fujii(ctr.) makes a comment

Picture taken at: Kyushu University Hospital



Teleconference view at Kyushu University Hospital

Picture taken at: Kyushu University Hospital



A group photo after the teleconference

Picture taken at: Kyushu University Hospital