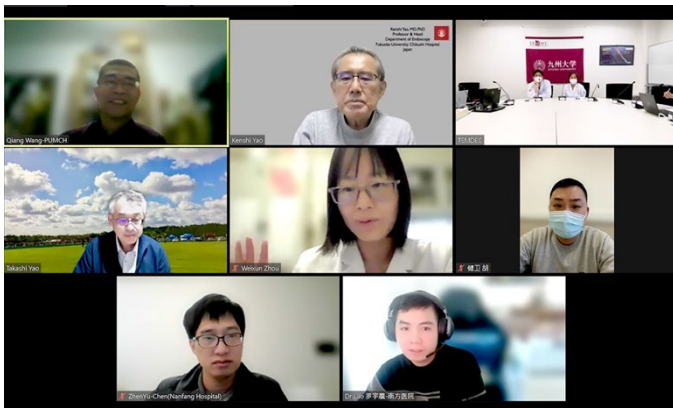


【 Connecting institutions 】

Peking Union Medical College H (China), Fudan U Zhongshan H (China), Tianjin Medical U (China), Nanfang H, Southern Medical U (China), Fukuoka U Chikushi H (Japan), Kyushu U H (Japan), Shandong Province H (China), Juntendo U (Japan), Beijing H (China), Cancer H, Chinese Academy of Medical Sciences (China), Beijing Friendship H, Capital Medical U (China)

【 Comments 】

We have an in-depth and thorough discussion of four cases in this teleconference. An EGC after ESD with ly(+) still needed surgery. For undifferentiated EGC, negative biopsy should be used as a routine method before ESD. A rare subtype of EGC: GAED, got successful resection by ESD. As to the polypoid lesion in gastric fundus, VS classification system can still be used to differentiate between benign and malignant lesions.



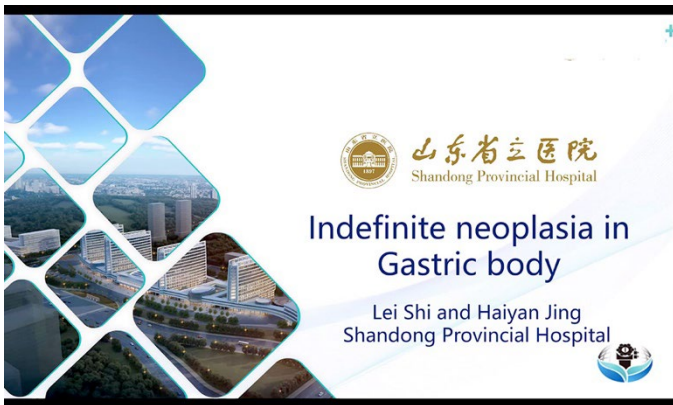
Monitor shows connected sites

Picture taken at : Kyushu University Hospital



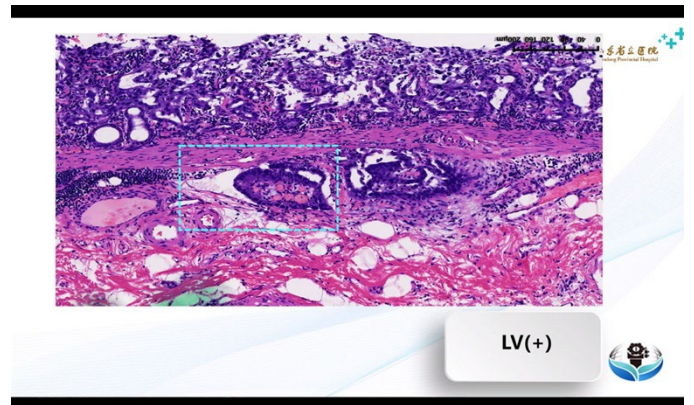
Teleconference view at Kyushu University Hospital

Picture taken at : Kyushu University Hospital




A presented slide

Picture taken at : Kyushu University Hospital



A presented slide

Picture taken at : Kyushu University Hospital



Dr. Haiyan Jing makes a presentation

Picture taken at : Shandong Province Hospital



Teleconference view at Kyushu University Hospital

Picture taken at : Kyushu University Hospital