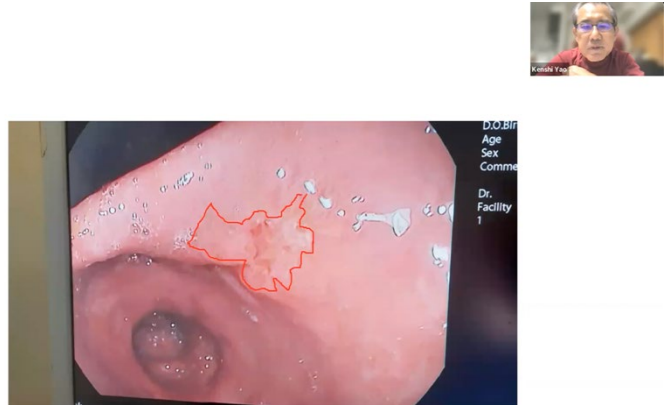



**【 Connecting institutions 】**  
 Jigme Dorji Wangchuck National Referral H (Bhutan), Khesar Gyalpo U of Medical Sciences of Bhutan (Bhutan), Gelephu Central Regional Referral H (Bhutan), Mongar Regional Referral H (Bhutan), Wangdue H (Bhutan), Royal Center of Disease Control, Bhutan (Bhutan), Fukuoka U Chikushi H (Japan), Oita U (Japan), Kyushu U H (Japan), Olympus Japan (Japan), Juntendo U (Japan), Tokyo Women's Medical U H (Japan), NPO Zero Helicobacter-related International Gastric cancer Network (Japan)

**【 Comments 】**  
 The gastric cancer suspected cases detected within 3 months in Bhutan were presented together with pathological findings by the Bhutanese doctors. Japanese professors pointed that taking clear photos is important for the accurate diagnosis. Presented cases suggested us the improvement of diagnostic skill of gastric cancer..

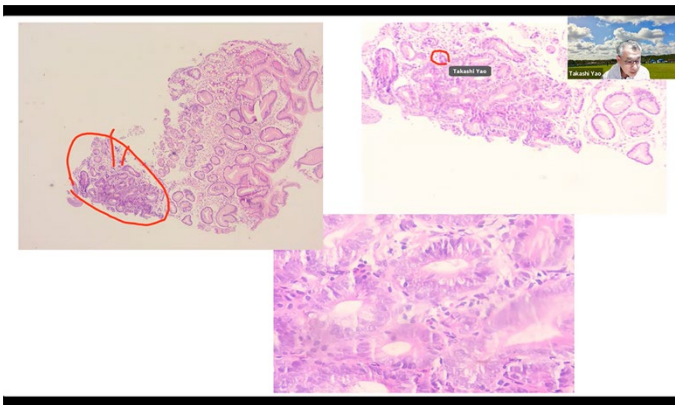


Monitor shows connected sites

A presentation slide

Picture taken at: Kyushu University Hospital

Picture taken at: Kyushu University Hospital

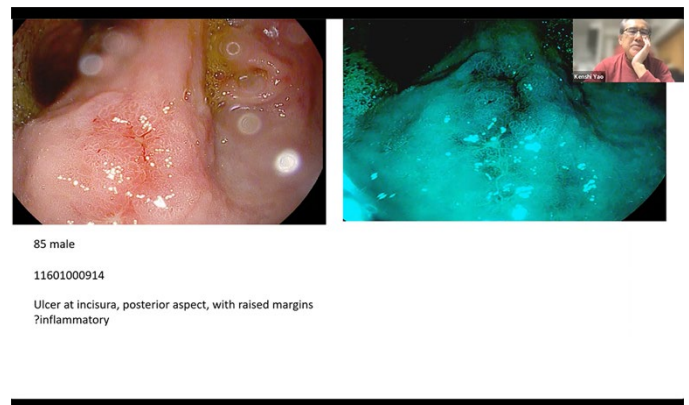


A presentation slide

Teleconference view at Kyushu University Hospital

Picture taken at: Kyushu University Hospital

Picture taken at: Kyushu University Hospital



Dr. Yao makes a comment

A presentation slide

Picture taken at: Kyushu University Hospital

Picture taken at: Kyushu University Hospital