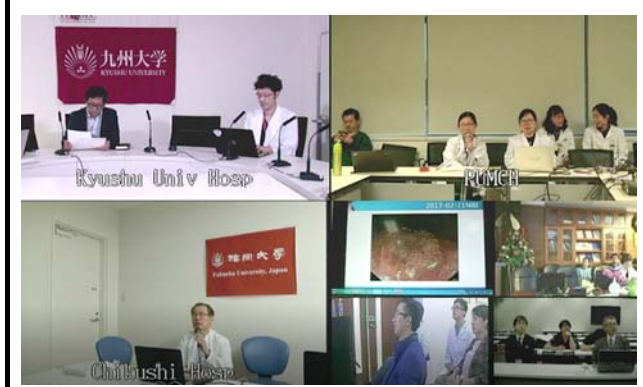

<p>【Event】 The 23rd Peking Early Gastric Cancer Teleconference</p>	<p>【Comments】 Doctors from 7 stations met again through internet and discussed cases of EGC with more than 20 sites on the streaming list. Four cases were provided by different stations and fully discussed within endoscopists and pathologists. A gastric polyp with irregular MVP which mimicked the EGC impressed everyone. Though there were some interruptions due to the unstable internet, the teleconference was successfully finished.</p>
<p>【Date】 2017.03.22</p>	
<p>【Venue】 Peking Union Medical College Hospital (China), Fudan University Zhongshan Hospital (China), Tianjin Medical University (China), Nanfang Hospital, Southern Medical University (China), Juntendo University (Japan), Fukuoka University Chikushi Hospital (Japan), Kyushu University Hospital (Japan)</p>	



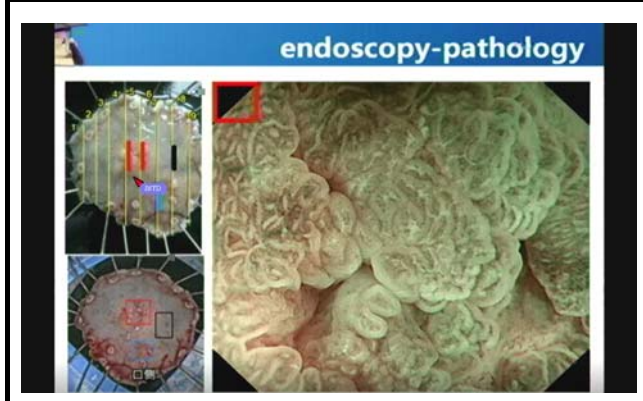
Monitor shows connected sites.

Picture taken at: Kyushu University Hospital



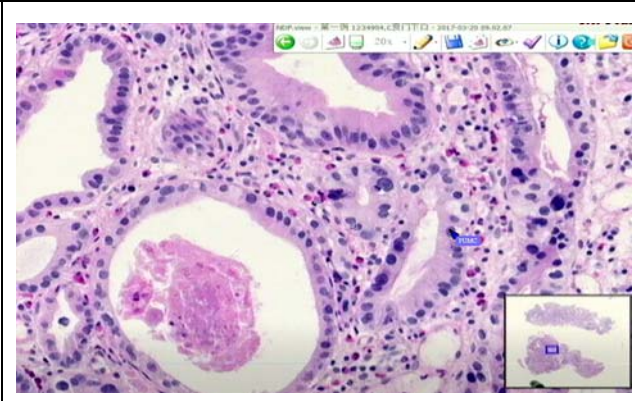
Teleconference view at Kyushu University Hospital.

Picture taken at: Kyushu University Hospital



A presented slide.

Picture taken at: Kyushu University Hospital



A discussion about pathology using Tele-pointer.

Picture taken at: Kyushu University Hospital



Teleconference view at Peking Union Medical College Hospital.

Picture taken at: Kyushu University Hospital



Dr. Joyama makes a comment.

Picture taken at: Kyushu University Hospital